

记临夏盆地维氏大唇犀一牙齿异常个体¹⁾陈少坤^{1,2} 邓涛² 何文³ 陈善勤³

(1 重庆中国三峡博物馆,重庆三峡古人类研究所 重庆 400015)

(2 中国科学院古脊椎动物与古人类研究所,脊椎动物进化系统学重点实验室 北京 100044)

(3 和政古动物化石博物馆 甘肃和政 731200)

摘要:临夏盆地已知的大唇犀(*Chilotherium* 属)共有3种,*C. primigenius*, *C. anderssoni* 和 *C. wimani*。其中,*C. wimani* 是临夏盆地晚中新世三趾马动物群中的优势种类,在临夏盆地的柳树组中部和上部的各个化石地点均有出土,时代为晚中新世中期。该种下颌主要特征表现在联合部强烈地横向扩展和i2巨大且内刃上翻。本文所述标本为一件带畸形牙齿的*C. wimani* 亚成年下颌,年龄约9岁,个体中等大小,其特征与*C. anderssoni* 相差较大,而与*C. wimani* 完全一致。其畸形之处表现在左、右两侧的p4为异常状态,并且在左侧还保留有dp4。左p4前后内外倒转,且下三角座仅为一锥形牙尖形态;右p4不仅内外反转,而且下三角座完全退失。这件标本从病因来看,左dp4的滞留很可能是左p4牙胚的不正常发育造成的,而左、右p4的畸形生长很可能是生物体遗传因素和营养不良共同造成的。*C. wimani* 的数量庞大,种间和种内竞争都很激烈。牙齿的畸形影响了上下牙的咬合状况,在环境恶劣、竞争激烈的情况下,功能劣势是致命的。

关键词:甘肃临夏盆地,晚中新世,大唇犀,牙齿畸形**中图分类号:**Q915.877 **文献标识码:**A **文章编号:**1000-3118(2011)02-0223-06A DENTAL PATHOLOGICAL DEFORMITY OF *CHILOTHERIUM WIMANI* FROM THE LINXIA BASIN OF GANSU, CHINACHEN Shao-Kun^{1,2} DENG Tao² HE Wen³ CHEN Shan-Qin³(1 Chongqing Three Gorges Institute of Paleoanthropology, China Three Gorges Museum Chongqing 400015
chenshaokun_ivpp@yahoo.com.cn)

(2 Key Laboratory of Evolutionary Systematics of Vertebrates, Institute of Vertebrate Paleontology and Paleoanthropology, Chinese Academy of Sciences Beijing 100044)

(3 Hezheng Paleozoological Museum Hezheng 731200)

Abstract *Chilotherium wimani* is the dominant species in the Late Miocene *Hipparion* fauna of the Linxia Basin. A sub-adult mandible belonging to *C. wimani* is described here. The unusual characters of this mandible are the retention of left dp4 and the morbid state of left and right p4. The left p4 exhibits anterior-posterior and labial-lingual reversion and the trigonid of this tooth is strongly tapered. The right p4 shows not only anterior-posterior reversion, but also the absence of trigonid. The retention of the left dp4 is induced likely by the abnormal growth of the left p4 germ, while the deformity of the left and right p4 may be caused by hereditary factors and/or malnutrition. The non-adaptive malocclusion would result in disadvantage in competition, and this functional disadvantage would be fatal under the likely condition of the harsh Late Miocene Linxia environment.

1) 国家自然科学基金项目(批准号:40730210, J0930007)、中国科学院知识创新工程重要方向项目(编号:KZCX2-YW-Q09, -120)和中国科学院脊椎动物进化系统学重点实验室开放课题基金(编号:2010LESV010)资助。

收稿日期:2010-04-26

Key words Linxia Basin, Gansu; Late Miocene; *Chilotherium wimani*; dental deformity

The three *Chilotherium* species of the Linxia Basin are *C. primigenius* Deng, 2006, *C. anderssoni* Ringström, 1924 and *C. wimani* Ringström, 1924. *C. primigenius* is the most primitive known species in this genus and found only from the Zhongmajia site, which is in the lower part of Liushu Formation (early Late Miocene, MN9) (Deng, 2006a). *C. anderssoni* is the dominant species in Baode, Shanxi (the age is about MN12), but in the Linxia Basin, this species is less common and only found from Qianzhuang and Bancaoling (Deng, 2006b,c). *C. wimani*, found at any fossil site in the middle and upper red clay of the Liushu Formation (MN10-11), is the dominant species in the Late Miocene *Hipparion* fauna of the Linxia Basin (Deng, 2006b). *C. wimani* is established on the materials from Fugu, Shaanxi and was at one time synonymized with *C. habereri* (Heissig, 1975). Deng (2001a,b; 2002) described more fossils belonging to *C. wimani* and revalidated its distinctiveness, and Chen et al. (2010) analyzed abundant skulls from the Linxia Basin, clearly establishing the diagnostic characters of *C. wimani*. The main characters of its mandible are symphysis expands transversely, and i2 is huge with an upturned medial flange. An abnormal mandible of *C. wimani* is described in this paper. Based on this mandible, some helpful information about this species and the Late Miocene *Hipparion* fauna from the Linxia Basin can be concluded.

The paleopathologic instances of fossil mammal teeth are relatively common, such as chiropteran *Myotis blythii* (Ghazali, 2008), carnivoran *Ailuropoda melanoleuca* (Wang and Wu, 1976), proboscidean *Mammuthus sungari* (Chow and Chang, 1959), pantodont *Coryphodon anthracoides* (Lucas and Schoch, 1987), and artiodactyl *Ovis* (Sapir-Hen et al., 2008). Other pathologic conditions have been recognized in Perissodactyla, for instance *Coelodonta antiquitatis* (Chow, 1961), *Hipparion* (Forsten, 1973), *Anisodon macedonicum* (de Bonis et al., 1995), and *Stephanorhinus hundsheimensis* (Koenigswald et al., 2007), etc.

Lower tooth nomenclature follows Qiu and Wang (2007, fig. 7). Measurements are given in mm. HMV: specimen prefix of the Hezheng Paleozoological Museum, Gansu, China.

Family Rhinocerotidae Owen, 1845

Subfamily Aceratheriinae Dollo, 1885

Tribe Chilotheriini Qiu et al., 1987

Genus *Chilotherium* Ringström, 1924

Chilotherium wimani Ringström, 1924

(Fig. 1; Table 1)

Described specimen HMV 1864, a sub-adult (about 9 years old) incomplete male mandible with all teeth; m3 erupting; ascending ramus, left i2 and the tip of right i2 broken.

Locality and age Shancheng in Majiaji Township, Hezheng County, Gansu Province, China; upper part of Liushu Formation, middle Late Miocene.

Comparison and classification The i1 is absent in this mandible. The i2s are erupting, broken on the left side, and the huge i2 has an upturned medial flange. Symphysis expands transversely. These characters indicate that this mandible represents a male belonging to *Chilotherium* (Deng, 2001b).

HMV 1864 is middle sized and its characters show it can be identified as *C. wimani*, rather than *C. anderssoni*. These characters are: tusk (i2) huge with a triangle cross section and extending outwards; symphysis long and its posterior border behind the p3 level, with dorsal and ventral concavities; horizontal ramus straight but curved at the medial part; mental foramen located under the posterior border of p3; i1 and dp1 absent.

Comparing HMV 1864 with other specimens of *C. wimani*, the most obvious difference is the anomalous left and right p4 and the retention of left dp4.

Left dp4: because of the permanent p4, the right dp4 should be replaced; while at the left side, dp4 has not been lost, but is displaced labially for the extrusion of p4 and m1. It is strongly worn and the crown is flat. This tooth is premolar shaped and the trigonid is smaller than the talonid.

Left p4: little worn. Anterior-posterior and labial-lingual structures are reversed, meaning that the talonid stands anteriorly to the trigonid. The talonid is a semicircular arc and the posterior valley opens to the labial side; the entoconid is the most developed cusp and is located at the labial side; the hypoconid is situated at the anterior part of the lingual side; metastylid is the weakest cusp and is located at the lingual side. The entolophid is wide and the hypolophid is weaker. The simple trigonid tapers, linking a typical cusp that stands at the midline of this tooth.

Right p4: moderately worn and only talonid present. This talonid is also a semicircular arc, the same as in the left p4. Its posterior valley opens to the labial side, which also means the metastylid and entoconid are located on the labial side, and these two cusps are more developed than the hypoconid.

Table 1 Measurements of *Chilotherium wimani* (HMV 1864) (mm)

Measurements	HMV 1864	Measurements	HMV 1864
Minimal width of symphysis	105.2	right p4 length	36.6
Maximal width of symphysis	129*	right p4 width	27.4
p2-m3 length	240.5	left p4 length	36.6
p2-p4 length	144.2	left p4 width	27.4
m1-m3 length	96.2	left dp4 length	29.3
Height of horizontal ramus in front of p3	52.5	left dp4 width	24.4

* Estimated value.

Pathological analysis Anomalies in fossil teeth are usually expressed as supernumerary (Wang and Wu, 1976; de Bonis et al., 1995; Koenigswald et al., 2007; Ghazali, 2008) or missing (Sapir-Hen et al., 2008), while deformities like the phenomenon expressed in this individual are relatively rare. Generally speaking, in rhinos, the anterior part of lower cheek teeth (the trigonid) is a “U” type and the posterior part (the talonid) is an “L” type (Qiu and Wang, 2007). All the teeth on HMV 1864 are “U+L” type except two p4s and both of them are very different from the same teeth on other *C. wimani* individuals, so these abnormal morphologic characters are most likely pathological.

Tooth deformities can have diverse causes, which can be divided into internal and external factors. Internal factors include heredity, mutation and other congenital elements, while the external factors include habits, environment and other postnatal conditions. The specimen described in this paper likely experienced both internal and external factors. The first one is internal factor. The morphological characters of left dp4 indicate that it was very normal before the eruption of left p4, but it has not been shed promptly after left p4 erupted, leading to the retention of this deciduous tooth in the jaw. This is a very common human dental pathology. Obviously the p4s had an abnormal state before their eruption, caused by developmental (genetic) factors. In addition, modern molecular biology has proven that the eruption of teeth is regulated by genes to some extent (Tiffée et al., 1999). The second set of factors is external. The growth and development of teeth have their particular schedule and sequence, and the retention or loss of deciduous teeth will affect the morphology and function of permanent teeth (Xu and Shao, 2007). Based on the left p4 of HMV 1864, the pathological changes of p4s exhibit not only anterior-posterior and labial-lingual reversal, but also the retention of left dp4, which caused the abnormal growth of the left p4. Without the impact of the stranded dp4, left p4 would very likely exhibit “normal growth”.

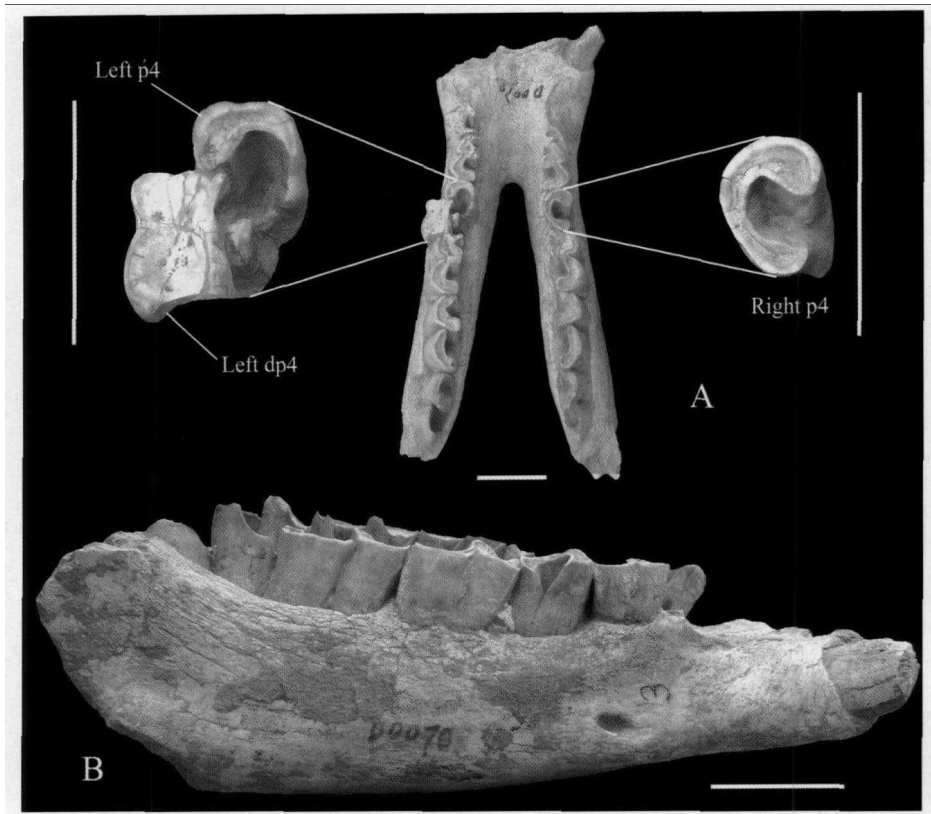


Fig. 1 Mandible of *Chilotherium wimani* (HMV 1864)
A. crown view; B. right lateral view; scale bars=5 cm

The deciduous teeth are stimulated by permanent teeth, from bottom to top, causing the apoptosis and resorption of the deciduous teeth roots, which leads the deciduous teeth to be replaced by the permanent teeth. There would be no more than three potential causes for the retention of a deciduous tooth: (1) the dislocation of permanent tooth germ, which means that the development of permanent tooth germ is abnormal; (2) deciduous tooth disease and secondary infection, which will lead to permanent tooth necrosis; (3) permanent tooth missed congenitally. Obviously, the pathology of HMV 1864 belongs to reason (1) with slight modification. The p4 root position should be normal and under the dp4's lingual side, but its structure and direction are wrong.

In humans, the initiation and development of tooth germs are regulated by growth factors and related genes. The antagonism between fibroblast growth factors (FGF) and bone morphogenetic protein (BMP) can control the expressed location of Paired Box Gene 9 in dental mesenchyme and Paired-like Homeodomain Transcription Factor 2 in the dental epithelium. The expression of FGF and BMP also determines the location of the tooth germ generation (Jiang and Wang, 2006). Perhaps, a similar mechanism akin to the abnormal expression of these two factors caused the pathological changes observed on HMV 1864.

Other important pathological changes are on right p4 which trigonid is missing and on left p4 which talonid shows a tapered shape. This is considered an abnormality of tooth shape in modern stomatology. Right p4 lacks talonid cusps altogether, and left p4 has a midline cusp deformity. The cusps of teeth develop from enamel nodules formed during the embryonic development. While the formation and development of enamel nodules are also regulated by genes. Enamel nodules,

as non-proliferated centers, activate the growth and development of surrounding cells to guide the formation of cusps (Wang et al., 2001). Therefore the formation of pathological cusps is very likely due to the mutation of related genes and the formation of a central cusp deformity attributes to excessive growth of a nodule, which results from the inaccurate order of gene expression. This interpretation may not be accurate since we cannot give fossils a modern physical examination.

Abnormality of tooth shape is due to the irregular development caused by a variety of obstacles during dentinal matrix formation or calcification. The reasons may relate to the malnutrition of the female parent or of the young (such as inadequate calcium, phosphorus, vitamin A, or D) or the regional infection of the upper and lower jaw in the young. But infection, for example parodontopathy, usually leads to the loss of teeth or the swelling of the jaw (e. g. Chow, 1961). Obviously infection is not consistent with the case in HMV 1864, because there is no anomaly of this mandible other than the pathological teeth. Probably malnutrition is a factor in this case.

Discussion During the Late Miocene, the Linxia Basin underwent severe drying and the climate was harsh (Liang and Deng, 2005). Dental abnormalities of HMV 1864 are probably caused by malnutrition, indicating that there were episodes of food shortage at least in the Late Miocene of the Linxia Basin. According to the taphonomy of the *Hipparion* fauna in the Linxia Basin, seasonal floods alternated with droughts, and climate had marked periodicity (Liang and Deng, 2005). The environmental indicators are consistent with the presence of malnutrition in wild animals.

The retention of human deciduous teeth often brings on irregularity of the dentition and the malocclusion. This phenomenon is in line with the mandible in this paper. The growth of pathology results in the loosing, relocation, elongation or loss of teeth, leading to secondary malocclusion and occlusal trauma. Simultaneously, the deformity of malocclusion damages the development of permanent teeth by the extrusion, occlusive weakness, untimely contact or other aspects of pathological dentition. This vicious cycle yields a competitive disadvantage for affected wild animals. On HMV 1864, left dp4 is retained and worn severely, standing at the labial side. Indeed, the occlusion of the upper and lower teeth in this mandible is affected since the ectoloph of P4 occludes with dp4 instead of p4. For all of the teeth, the left row is slightly less worn than the right, meaning the presence of left dp4 weakened the abrasion of the teeth. Koenigswald et al. (2007) described a juvenile lower jaw (7 years old) of *Stephanorhinus hundsheimensis* from the Middle Pleistocene in the Wiesbaden, Germany. In their mandible, a pair supernumerary teeth erupted between normal p2 and p3. Koenigswald et al. (2007) thought that the animal's occlusion was compromised by the anomaly, and the functional disadvantage was fatal under the condition of a harsh environment and fierce competition. In this paper, their viewpoint is supported by a comparable observation.

Via comparison with the African white rhino (*Ceratotherium simum*), HMV 1864 can be regarded as 9 years old, at sub-adult stage (Hillman-Smith et al., 1986; Liang and Deng, 2005). In the Late Miocene of the Linxia Basin, *C. wimani* was highly abundant, and the inter- and intra-specific competition were likely very fierce. Another skull of this species is clearly scarred by bites of giant percrocutid (*Dinocrocuta gigantea*) (Deng and Tseng, 2010). On the intact tusks (i2s), fight marks are very common. The malnutrition and death before maturation of HMV 1864 can confirm the wicked climate and ruthless competition for this species in the Late Miocene of the Linxia Basin.

Acknowledgements We are grateful to Lawrence J. Flynn from Peabody Museum of Harvard University and Zhijie Jack Tseng from Natural History Museum of Los Angeles County for their improvement of the manuscript in English and valuable comments. Miss Luo Meijuan from Chongqing Stomatological Hospital is also thanked for her kind help.

References

- Bonis L de, Bouvrain G, Koufos G et al., 1995. Un crâne de Chalicothère (Mammalia, Perissodactyla) du Miocène supérieur de Macédoine (Grèce): remarques sur la phylogénie des Chalicotheriinae. *Palaeovertebrata*, **24**: 135–176
- Chen S K, Deng T, Hou S K et al., 2010. Sexual dimorphism in perissodactyl rhinocerotid *Chilotherium wimani* from the Late Miocene of the Linxia Basin (Gansu, China). *Acta Palaeont Pol*, **55**: 587–597
- Chow B X(周本雄), 1961. Note on a pathologic mandible of woolly rhinoceros from Siki, Ningsia. *Vert PalAsiat(古脊椎动物学报)*, (1): 43–46(in Chinese with English summary)
- Chow M C(周明镇), Chang Y P(张玉萍), 1959. Pleistocene Mammalian Fossils from the Northeastern Provinces. Beijing: Science Press. 22–34(in Chinese with English resume)
- Deng T(邓涛), 2001a. New materials of *Chilotherium wimani* (Perissodactyla, Rhinocerotidae) from the Late Miocene of Fugu, Shaanxi. *Vert PalAsiat(古脊椎动物学报)*, **39**(2): 129–138(in Chinese and English)
- Deng T(邓涛), 2001b. Cranial ontogenesis of *Chilotherium wimani* (Perissodactyla, Rhinocerotidae). In: Deng T, Wang Y eds. Proceedings of the 8th Annual Meeting of the Chinese Society of Vertebrate Paleontology. Beijing: China Ocean Press. 101–112
- Deng T(邓涛), 2002. Limb bones of *Chilotherium wimani* (Perissodactyla, Rhinocerotidae) from the Late Miocene of the Linxia Basin in Gansu, China. *Vert PalAsiat(古脊椎动物学报)*, **40**(4): 305–316
- Deng T, 2006a. A primitive species of *Chilotherium* (Perissodactyla, Rhinocerotidae) from the Late Miocene of the Linxia Basin (Gansu, China). *Cainoz Res*, **5**: 93–102
- Deng T, 2006b. Neogene rhinoceroses of the Linxia Basin (Gansu, China). *Courier Forsch Inst Senckenberg*, **256**: 43–56
- Deng T(邓涛), 2006c. Chinese Neogene mammal biochronology. *Vert PalAsiat(古脊椎动物学报)*, **44**(2): 143–163
- Deng T, Tseng Z J, 2010. Osteological evidence for predatory behavior of the giant percocutid (*Dinocrocota gigantea*) as an active hunter. *Chinese Sci Bull*, **55**: 1790–1794
- Forsten A, 1973. Abnormal enamel morphology in fossil equid teeth. *J Mammal*, **54**: 255–258
- Ghazali M A, 2008. Extra upper premolars in a specimen of *Myotis blythii* (Chiroptera, Vespertilionidae). *Vestn Zool*, **42**(5): 91–93
- Heissig K, 1975. Rhinocerotidae (Mammalia) aus dem jungtertiär Anatoliens. *Geol Jahrb*, **15**: 145–151
- Hillman-Smith A K K, Owen-Smith N, Anderson J L et al., 1986. Age estimation of the white rhinoceros (*Ceratotherium simum*). *J Zool, Ser A*, **210**: 335–379
- Jiang B Z(蒋备战), Wang Z L(王佐林), 2006. Progress of the related signaling molecules and genes about the initiation of tooth germ. *J Ora Maxil Surg(口腔颌面外科杂志)*, **16**(3): 278–281(in Chinese)
- Koenigswald W V, Smith B H, Keller T et al., 2007. Supernumerary teeth in a subadult rhino mandible (*Stephanorhinus hundsheimensis*) from the Middle Pleistocene of Mosbach in Wiesbaden (Germany). *Paläont Z*, **81**(4): 416–428
- Liang Z(梁忠), Deng T(邓涛), 2005. Age structure and habitat of the rhinoceros *Chilotherium* during the Late Miocene in the Linxia Basin, Gansu, China. *Vert PalAsiat(古脊椎动物学报)*, **43**(3): 219–230(in Chinese with English summary)
- Lucas S G, Schoch R M, 1987. Paleopathology of early Cenozoic *Coryphodon* (Mammalia; Pantodonta). *J Vert Paleont*, **7**: 145–154
- Qiu Z X(邱占祥), Wang B Y(王伴月), 2007. Paracerthere fossils of China. *Palaeont Sin(中国古生物志)*, **29**: 1–396(in Chinese with English summary)
- Ringström T, 1924. Nashörner der *Hipparion*-fauna Nord-Chinas. *Palaeont Sin*, **1**(4): 1–159
- Sapir-Hen L, Bar-Oz G, Hershkovitz I et al., 2008. Paleopathology survey of ancient mammal bones in Israel. *Verter Zootech*, **42**: 62–70
- Tiffée J, Xing L, Nilsson S et al., 1999. Dental abnormalities associated with failure of tooth eruption in src knockout and op/op mice. *Calcif Tissue Int*, **65**: 53–83
- Wang L H(王令红), Wu M L(吴茂霖), 1976. A dental anomaly of *Ailuropoda melanoleuca baconi*. *Vert PalAsiat(古脊椎动物学报)*, **14**(4): 263–266(in Chinese with English abstract)
- Wang Y L(王颖莉), Wang J D(王嘉德), Gao Y(高岩), 2001. Genetic control of dental patterning. *Chin J Stomatol(中华口腔医学杂志)*, **36**(3): 236–238(in Chinese)
- Xu L(徐璐), Shao J L(邵金陵), 2007. Eruption time and sequence of permanent teeth and its relationship with malocclusions. *Chin J Conserv Dent(牙体牙髓牙周病学杂志)*, **17**(4): 236–239(in Chinese with English abstract)