

## Identification of Zhoukoudian *Homo erectus* brain asymmetry using 3D laser scanning

WU XiuJie<sup>1\*</sup> & PAN Lei<sup>1,2</sup>

<sup>1</sup> Key Laboratory of Evolutionary Systematics of Vertebrates, Institute of Vertebrate Paleontology and Paleoanthropology, Chinese Academy of Sciences, Beijing 100044, China;

<sup>2</sup> Graduate University of the Chinese Academy of Sciences, Beijing 100049, China

Received January 4, 2011; accepted March 23, 2011

Endocasts are important materials used for the study of human brain evolution, and allow examination of the external features of brain anatomy from the inside the cranium. Studies examining brain asymmetries in fossil hominids are usually limited to scoring of differences in hemisphere protrusion rostrally and caudally, or to comparing the width of the hemispheres. In the present study, using 3D laser scanning, we examined asymmetries of the hemisphere volumes and surface areas in the Zhoukoudain (ZKD) *Homo erectus*, dated to 0.4–0.8 Ma. Compared with modern endocasts, we found that the absolute hemisphere volumes and surface areas exhibited no significant asymmetries in the ZKD or in modern specimens. However, the relative hemisphere volumes against surface areas differed between the two groups. When comparing the relative sizes between the left and right hemispheres, the ZKD specimens exhibited a greater variation than in the modern humans; there were no differences in the two hemispheres in the ZKD specimens, while in the modern endocasts the left hemisphere was significantly greater than the right hemisphere. These data suggest that brain asymmetries originated from relative brain sizes rather than absolute brain volumes during human evolution. These anatomical changes are likely related to the origin of human brain lateralization.

### Zhoukoudian *Homo erectus*, brain asymmetry, hemisphere volume, surface area, brain evolution

**Citation:** Wu X J, Pan L. Identification of Zhoukoudian *Homo erectus* brain asymmetry using 3D laser scanning. Chinese Sci Bull, 2011, 56: 2215–2220, doi: 10.1007/s11434-011-4512-1

It is well established that each hemisphere of the brain specializes in certain activities, a phenomenon termed brain asymmetry, and the organization of the brain is closely related to brain function [1]. In modern humans, numerous anatomical and X-ray, CT, and MRI imaging studies have documented anatomical cerebral asymmetries between the hemispheres, which include the weight of the hemisphere [2], the length of the sigmoid fissure [3], the flow direction of the venous sinuses [4], the protrusion degree of the frontal pole and the occipital pole [5,6], the number of nerve cells [7], the patterns of brain sulcus and gyrus [8], the size of the lateral ventricle [9], and the rates of cerebral maturation [10]. Brain asymmetries have also been correlated with asymmetrical behavioral traits including language, handed-

ness, musical talents, and visuospatial abilities [11].

For fossil hominids, the soft brain tissue was removed during fossilization. As such, endocasts are the direct material for the study of brain asymmetries. The endocast is the impression taken directly from the inside of a cranium that retains the surface features of the brain, and produces the most original material for studies of human brain evolution [12]. The structure of the human brain is extremely complex and is composed of multiple sulci and gyri. Even though endocasts reflect the surface of the brain, the sulci are not very clear compared with the brain itself. The most common landmarks that can be seen on endocasts are the coronal suture, sagittal suture, lambdoidal suture, and lateral sulcus, although these endocast landmarks are not very consistent with those seen on the brain. Nevertheless, as we know the variation of the structural organization of the brain, we can

\*Corresponding author (email: wuxijie@ivpp.ac.cn)

determine the general shape of the brain by measuring the endocranial cast. Analysis of fossil hominid endocasts allows inference of functional anatomy, physiology, and phylogeny.

Studies examining cerebral asymmetries in fossil hominids are usually limited to scoring of which hemisphere protruded further rostrally and caudally, or to comparisons of which hemisphere was wider [4,6,13,14]. Paleoanthropologists studying the fossil endocasts of *Australopithecus*, *Homo habilis*, *Homo erectus*, Neanderthals, and *Homo sapiens* have reported that almost all brain endocasts display distinct cerebral asymmetry. The most common and distinctive pattern is a dominance of the right frontal and left occipital lobes [13,15]. The increase in brain complexity, as seen in advanced tool using and symbolic language, is linked to these cerebral asymmetries [11,16]. It is likely that cerebral asymmetry and handedness have evolved very early in human evolution. Asymmetries seen in comparative studies of human fossil endocasts provide strong evidence for phylogenetic origins of brain lateralization.

The ZKD is the earliest *Homo erectus* site ever found in China. Since the official excavation in 1927, a group of six nearly complete crania were discovered in ZKD Locality 1. From these, six ZKD *Homo erectus* endocasts were reconstructed from the original cranium fossils, and are termed: ZKD II, III, V, X, XI and XII (Table 1). From the first reconstruction of the endocast ZKD *Homo erectus* (skull III), the left inferior frontal gyrus (Broca's area), which is associated with speech functions, was larger than the right hemisphere, suggestive of cerebral asymmetry [19]. Subsequently, the endocasts of ZKDII, ZKD X, ZKD XI and ZKD XII were reconstructed from the original skull fossils, and it was suggested that the ZKD specimens exhibited a larger left hemisphere than the right hemisphere [20,21]. Finally, reconstruction of the endocasts of ZKD V [22] suggested broader frontal and occipital lobes when compared with the other ZKD endocasts [23,24], which are similar to modern humans [13,14].

Currently, the asymmetrical studies on the ZKD specimens are restricted to the comparison of the protruding level or width between the two hemispheres. Although it was suggested that the ZKD *Homo erectus* might exhibit a larger left hemisphere than the right hemisphere, the subsequent studies did not examine similar parameters. In this study, we used a 3D laser surface technique to scan the ZKD *Ho-*

*mo erectus* endocasts, from which we reconstructed 3D brain images. Using these methods we were able to calculate absolute and relative volumes and surface areas of two hemispheres.


## 1 Materials and methods

### 1.1 Materials

Details of the six ZKD endocasts used in this study are shown in Figure 1 and Table 1. ZKD II, ZKD III, ZKD V, ZKD X, ZKD XI, and ZKD XII were from the collections of the Institute of Vertebrate Paleontology and Paleoanthropology, Chinese Academy of Sciences. Comparative endocasts of 42 modern humans (21 males and 21 females) were from RLH's collection at Columbia University and the medical department at the University of the Witwatersrand.

### 1.2 3D laser scanning

Using a NextEngine Model 2020i Desktop 3D Scanner (www.NextEngine.com), the six ZKD specimens and 42 modern endocasts were scanned and created into 3D models. The digitizer-based and 3D model-based coordinate measurements had overall standard deviations of  $\pm 0.79$  and  $\pm 1.05$  mm, respectively [25]. The scanner is in a portable shape, and can capture full-color 3D images with high-measurement accuracy. This scanner is an excellent tool for the study of skulls and endocasts. 3D models were imported into Rapidworks™ software program (NextEngine Inc,



**Figure 1** The six ZKD endocasts used in our study, showing left lateral views. (a) ZKD III; (b) ZKD II; (c) ZKD X; (d) ZKD XI; (e) ZKD XII; (f) ZKD V.

**Table 1** The ZKD *Homo erectus* used

	Individual	Year of discovery	Date (Ma) [17]	Cranial capacity (cm <sup>3</sup> ) [18]
ZKD III	Locus E	1929	>0.80	915
ZKD II	Locus D	1930	0.68–0.78	1020
ZKD X	Locus L I	1936	0.68–0.78	1225
ZKD XI	Locus L II	1936	0.68–0.78	1015
ZKD XII	Locus L III	1936	0.68–0.78	1030
ZKD V	Locus H III	1934, 1966	>0.40	1140

Santa Monica, California, US) on a Dell workstation. To standardize the measuring procedure, each endocast was placed on a flat surface with the horizontal plane along the X-axis of the frontal and occipital poles parallel to the flat surface whether rotated for a superior or lateral view (Figure 2(a)), and the coordinate system of the vertical plane along the Y-axis passing through the sagittal center of the two hemispheres (Figure 2(b), (c)). The coordinate system of each model was adjusted so that the axes were made normal to this plane. Along the Y-axis plane, each endocast was split into the left hemisphere (Figure 2(f)) and the right hemisphere (Figure 2(h)).

### 1.3 Measurements and statistics

We determined the absolute value of the left hemisphere volume, right hemisphere volume, left hemisphere surface area, and right hemisphere surface area using Rapidworks software. As the absolute brain size relates to the body size, we used the “hemisphere relative size” to reduce the influence of the predicted body size. By scaling hemisphere volume against surface area, it is possible to make in-

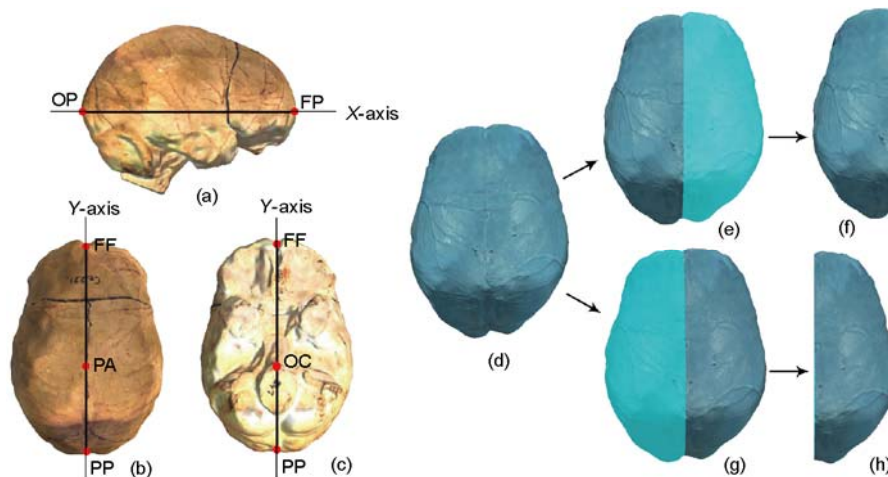
ter-specific comparisons between the ZKD *Homo erectus* and the modern specimens. The formula for the hemisphere relative size is: (1) Left hemisphere relative size (%) =  $100 \times \text{left hemisphere volume}^{1/3} / \text{left hemisphere surface area}^{1/2}$ ; (2) Right hemisphere relative size (%) =  $100 \times \text{right hemisphere volume}^{1/3} / \text{right hemisphere surface area}^{1/2}$ .

Statistical analyses were performed using SPSS 13.0 (SPSS Inc, Chicago, Illinois, US). Paired samples *t*-test was used to determine whether the left hemispheres were different from the right hemispheres between the ZKD specimens and the modern endocasts.

## 2 Results

### 2.1 Comparisons between left and right hemisphere volumes

Metric data on the ZKD and the modern humans in our samples are shown in Table 2. The right hemisphere volumes were larger than the left hemisphere volumes for ZKD II, ZKD III, ZKD V, ZKD XI and ZKD XII, and the differences between the two hemispheres were 12.2, 5.6, 7.8, 25.6,



**Figure 2** Virtual 3D endocasts and methods used to split the left and right hemispheres. (a) Standard X-axis reference plane; (b),(c) standard Y-axis reference plane. (d)–(f) Methods used to split the left hemisphere; (d), (g), (h) methods used to split the right hemisphere. FP, frontal pole; OP, occipital pole; FF, center of two frontal poles; PA, center of two parietal lobes; PP, center of two occipital poles; OC, anterior lip of the foramen magnum.

**Table 2** The hemisphere volumes ( $\text{cm}^3$ ), surface areas ( $\text{cm}^2$ ), and relative hemisphere sizes (%) of ZKD *Homo erectus* and modern humans

	Left hemisphere			Right hemisphere		
	Volume	Surface areas	Relative size	Volume	Surface areas	Relative size
ZKD II	472.0	251.4	49.1	484.2	255.7	49.1
ZKD III	432.5	244.8	48.3	438.1	245.7	48.5
ZKD V	559.8	309.1	46.9	567.6	310.2	47.0
ZKD X	634.4	314.2	48.5	584.7	298.8	48.4
ZKD XI	504.7	271.9	48.3	530.3	282.0	48.2
ZKD XII	516.2	274.8	48.4	529.5	275.1	48.8
Modern humans	678.7(511.4–843.2)	336.7(280.9–386.8)	47.9(47.1–48.8)	680.3(513.5–868.4)	337.9(280.6–397.2)	47.8(47.1–48.7)

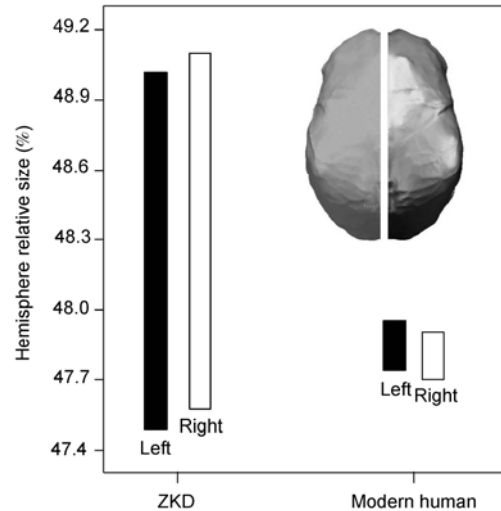
and 13.3 cm<sup>3</sup>, respectively. For ZKD X, the left hemisphere volume was larger than the right hemisphere volume, and the difference between the two hemispheres was 49.7 cm<sup>3</sup>. For the modern humans, the average left hemisphere volume was 678.7 cm<sup>3</sup> (range, 511.4–843.2 cm<sup>3</sup>), and the average right hemisphere volume was 680.3 cm<sup>3</sup> (range, 513.5–868.4 cm<sup>3</sup>). There were no differences between the left versus the right hemisphere volumes among the six ZKD specimens and the modern humans in our study (Table 3).

## 2.2 Comparisons between left and right hemisphere surface areas

The right hemisphere surface area was larger than the left hemisphere for ZKD II, ZKD III, ZKD V, ZKD XI, and ZKD XII, and the differences between the two hemispheres were 4.3, 0.9, 1.1, 10.1, and 0.3 cm<sup>3</sup>, respectively. The left hemisphere surface area for ZKD X was larger than the right hemisphere surface area, and the difference between the two hemispheres was 5.4 cm<sup>3</sup>. For the modern humans, the left hemisphere surface area ranges 280.9–386.8 cm<sup>3</sup> (average, 336.7 cm<sup>3</sup>), and the right hemisphere volume ranges 280.6–397.2 cm<sup>3</sup> (average, 337.9 cm<sup>3</sup>). There was no difference between the left versus the right surface area among the six ZKD specimens and the modern humans in our sample (Table 3).

## 2.3 Comparisons between the left and right hemisphere relative sizes

The relative size of the right hemisphere was larger than the left hemisphere for ZKD III, ZKD V, and ZKD XII, and the differences between the two hemispheres were 0.2%, 0.1%, and 0.4%, respectively. The left hemisphere relative size was larger than the right hemisphere for ZKD X and ZKD XI. ZKD II (left, 49.1%; right, 49.1%) and ZKD V (left, 46.9%; right, 47.0%) were higher than the range of the modern humans (left range, 47.1%–48.8%; right range, 47.1%–48.7%). There were no differences between the left and right hemisphere relative sizes among the ZKD specimens, while there was a difference for the modern humans (Table 3). The relative sizes of the left and right hemispheres of the ZKD and modern humans with a 95% individual prediction interval are shown in Figure 3. The variation range of the hemisphere relative sizes of the ZKD specimens were larger than for the modern humans in our sample.



**Figure 3** The left and right hemisphere relative sizes of the ZKD and modern humans (95% individual prediction interval).

## 3 Discussion and conclusions

The overall increase in brain size is a critical feature of human evolution. The size of the brain can change in terms of both absolute brain volume and relative brain size. Absolute brain volume is the actual size of a brain, usually expressed by a measure of weight and volume. Relative brain size is the relationship between size of the brain and the body. In the present study, using the 3D laser surface technique, we studied the brain asymmetry of the ZKD *Homo erectus*, and showed that the brain asymmetry is related to relative size rather than absolute volume.

The geological age of the ZKD specimens in our study is 40–80 Ma [17]. ZKD specimens retained a cranial capacity between 915–1225 cm<sup>3</sup> (Table 1), which is in the range of *Homo erectus* from 600–1251 cm<sup>3</sup> [26], and lower than the average of modern humans at 1390 cm<sup>3</sup> [27]. The cranial capacity of modern humans ranges from 1140–1600 cm<sup>3</sup> [27], and although some individuals have small brain size close to *Homo erectus*, the morphological features of the modern humans are different from the early fossil humans. The *Homo erectus* has a low brain height, a low position of the greatest breadth, flat and narrow frontal lobes, depressed parietal lobes, a strong posterior projection of the occipital lobes, and elongated and quite separated cerebella lobes. Compared with the *Homo erectus*, the height of brain of the modern humans are tall, the frontal lobes are full and wide,

**Table 3** Left and right hemisphere volumes, surface areas (cm<sup>2</sup>), and relative hemisphere sizes of ZKD *Homo erectus* and modern humans

	Left and right hemisphere volumes	Left and right surface areas	Left and right hemisphere relative sizes
ZKD (n=6)	0.829	0.953	0.341
Modern humans (n=42)	0.680	0.330	0.046*

\*  $P < 0.05$ .

the parietal lobes are bulgy, the occipital lobes display a steady reduction, and the cerebella lobes become tighter, more globular, and approach the midline [28]. During human evolution, with the enlargement of brain size, brain morphological features experienced significant changes, but the ratio of the two hemispheres volumes was not modified, and neither the ZKD nor the modern specimens display clear cerebral asymmetry.

We found no difference in the relative size of the hemispheres in the ZKD specimens, but did find a difference in modern humans. The variation range and individual differences in the ZKD specimens were greater than that in the modern humans. During the evolution from the ZKD *Homo erectus* to the modern humans there have been complex changes in the structural asymmetries between the two hemispheres, and this expansion of various brain structures may be functional. The organization of the brain structure is more important than the brain size [29]. Brain asymmetry is not a unique characteristic of humans, with brain asymmetries also present in birds, monkeys, and apes [30]. This lateralization is thought to originate from evolutionary, hereditary, developmental, experience, and pathological factors [31].

Brain enlargement is associated with functional complexity; however, there is no strong direct relationship between brain size and intelligence among modern humans. Intelligence considered mainly influenced by the environment after birth [32]. Interestingly, the increase in cranial capacity does not appear to be a unidirectional trend, with recent studies indicating a decrease in cranial capacities by 95–165 mL for males and 74–106 mL for females in certain populations during the Holocene [33,34]. In studies examining the fossil endocasts of *Australopithecus*, *Homo habilis*, *Homo erectus*, Neanderthals, and *Homo sapiens*, almost all brain endocasts displayed distinct cerebral asymmetry. The Broca's speech area of apes is not enlarged, while in *Australopithecus africanus*, *Homo habilis*, and *Homo erectus* this area can be clearly observed on the left endocast. It is possible that the speech center has emerged during the time of *Australopithecus* [16], as some studies have suggested that the brain size of *Australopithecus* is too small to have language ability. The endocast from the 2.0 Ma KNM-ER 1470 fossil displays a sulcal pattern in the left frontal lobe that is similar to modern humans. However, this does not indicate that *Homo habilis* used language as we know it. With an enlarged brain, brain function became more complex, which likely provided the ability for humans to communicate with each other using language. It remains unclear whether the Broca's area of *Homo erectus* was associated with language-like abilities or tool making. At present, there are two anatomical indicators that *Homo erectus* could not speak: first, respiratory tract reconstruction suggests that *Homo erectus* had a short larynx and was unlikely to pronounce vowels; second, the thoracic vertebral canal and thoracic spinal nerves of *Homo erectus* were smaller than

that of modern humans. As such, the respiratory system of *Homo erectus* was not strong enough to control breathing, which is essential for speech [35].

In summary, based on endocast studies, we found that the ZKD and modern specimens exhibit similar symmetries for hemisphere volumes and surface areas, but markedly differ with respect to hemisphere relative sizes. Asymmetries were found for hemisphere relative sizes of the modern humans, but not in the ZKD specimens. The anatomical structures of the ZKD brains likely differ from the modern humans, while that ZKD *Homo erectus* had no ability to communicate with each other in the form of language. During human evolution, brain anatomical asymmetries experienced marked changes, and certain human abilities including language, intelligence, and cognition are likely related to these asymmetrical changes.

We would like to thank Professor Ralph Holloway from Columbia University, and Professor Ronald Clarke from University of the Witwatersrand, for supplying the modern endocasts. This work was supported by the National Natural Science Foundation of China (40972017), the Knowledge Innovative Program of the Chinese Academy of Sciences (KZCX2-YW-159 and XDA05130100) and the International Cooperation Program of MST of China (2009DFB20580).

- Richard G P. Structural asymmetries of the human brain and their disturbance in schizophrenia. *Schizophr Bull*, 1999, 25: 121–139
- Pilcher D L, Hammock E A D, Hopkins W D. Cerebral volumetric asymmetries in non-human primates: A magnetic resonance imaging study. *Laterality*, 2001, 6: 165–179
- Cunningham D J. Contribution to the surface anatomy of the cerebral hemispheres. *Cunningham Memoirs (R Irish Acad)*, 1892, 7: 372
- Le May M. Morphological cerebral asymmetries of modern man, fossil man and nonhuman primate. *Ann N Y Acad Sci*, 1976, 280: 349–366
- Le May M, Culebras A. Human brain: Morphologic differences in the hemispheres demonstrable by carotid arteriography. *N Engl J Med*, 1972, 287: 168–170
- Le May M, Billing M S, Geschwind N. Asymmetries of the brains and skulls of nonhuman primates. In: Armstrong E, Falk D, eds. *Primate Brain Evolution, Methods and Concepts*. New York: Plenum Press, 1982. 263–277
- Scheibel A B, Paul L A, Fried I, et al. Dendritic organization of the anterior speech area. *Exp Neurol*, 1985, 87: 109–117
- Davatzikos C, Bryan R N. Morphometric analysis of cortical sulci using parametric ribbons: A study of the central sulcus. *J Comput Assist Tomogr*, 2002, 26: 298–307
- Shenton M E, Kikinis R, McCarley R W, et al. Application of automated MRI volumetric measurement techniques to the ventricular system in schizophrenics and normal controls. *Schizophr Res*, 1991, 5: 103–113
- Taylor D C. Different rates of cerebral maturation between sexes and between hemispheres. *Lancet*, 1969, 2: 140–142
- Galaburda A M, Le May M, Kemper T L, et al. Right-left asymmetries in the brain. *Science*, 1978, 199: 852–856
- Wu X J, Liu W, Norton C J. Endocast — the direct evidence and recent advances in the study of human brain evolution. *Prog Nat Sci*, 2007, 17: 993–1002
- Holloway R L, De La Coste-Lareyondie M C. Brain endocast asymmetry in pongids and Hominids: some preliminary findings on the paleontology of cerebral dominance. *Am J Phys Anthropol*, 1982, 58: 101–110

- 14 Zilles K, Dabringhaus A, Geyer S, et al. Structural asymmetries in the human forebrain and the forebrain of non-human primates and rats. *Neurosci Biobehav Rev*, 1996, 20: 593–605
- 15 Falk D. Evolution of cranial drainage in hominids: Enlarges occipital/marginal sinuses and emissary foramina. *Am J Phys Anthropol*, 1986, 70: 311–324
- 16 Tobias P V. Recent advances in the evolution of the hominids with especial reference to brain and speech. *Pontificiae Acad Sci*, 1983, 50: 85–140
- 17 Shen G, Gao X, Gao B, et al. Age of Zhoukoudian *Homo erectus* determined with  $^{26}\text{Al}/^{10}\text{Be}$  burial dating. *Nature*, 2009, 458: 198–200
- 18 Weidenreich F. The skull of *Sinanthropus pekinensis*: A comparative study on a primitive hominid skull. *Pal Sin New Ser*, 1943, 10: 108–113
- 19 Black D. The brain cast of *Sinanthropus*—A review. *J Comp Neurol*, 1932, 56: 361–366
- 20 Weidenreich F. Observations on the form and proportions of the endocranial casts of *Sinanthropus pekinensis* and the great apes: A comparative study of brain size. *Pal Sin Ser D*, 1936, 7: 1–50
- 21 Weidenreich F. The ramification of the middle meningeal artery in fossil Hominids and its bearing upon phylogenetic problems. *Pal Sin N S D*, 1938, 110: 1–16
- 22 Qiu Z L, Gu Y M, Zhang Y Y, et al. Newly discovered *Sinanthropus* remains and stone artifacts at Zhoukoudian. *Vertebr Palasiatica*, 1973, 11: 109–131
- 23 Wu X J, Schepartz L, Liu W. Endocranial cast of Zhoukoudian skull V: A new *Homo erectus* brain endocast from China. *Proc R Soc B*, 2010, 277: 337–344
- 24 Wu X J, Schepartz L, Norton C J. Morphological and morphometric analysis of variation in the Zhoukoudian *Homo erectus* brain endocasts. *Quat Int*, 2010, 211: 4–13
- 25 Sholts S B, Flores L, Walker P L, et al. Comparison of coordinate measurement precision of different landmark types on human crania using a 3D laser scanner and a 3D digitiser: Implications for applications of digital morphometrics. *Int J Osteoarchaeol*, 2010, doi: 10.1002/oa.1156
- 26 Rightmire G P. Brain size and encephalization in early to mid-Pleistocene *Homo*. *Am J Phys Anthropol*, 2004, 124: 109–123
- 27 Wu X J, Liu W, Dong W, et al. The brain morphology of Homo Liujiang cranium fossil by three-dimensional computed tomography. *Chinese Sci Bull*, 2008, 53: 2513–2519
- 28 Weaver A H. Reciprocal evolution of the cerebellum and neocortex in fossil humans. *Proc Natl Acad Sci USA*, 2005, 102: 3576–3580
- 29 Holloway R L. The evolution of the primate brain: Some aspects of quantitative relations. *Brain Res*, 1968, 7: 121–172
- 30 Geschwind N, Galaburda A M. Cerebral lateralization: Biological mechanisms, associations and pathology. *Arch Neurology*, 1985, 42: 428–459
- 31 Toga W, Thompson P M. Mapping brain asymmetry. *Nat Rev Neurosci*, 2003, 4: 37–48
- 32 Willerman L, Rutledge J N, Bigler E D. *In vivo* brain size and intelligence. *Intelligence*, 1991, 15: 223–228
- 33 Henneberg M. Decrease of human skull size in the Holocene. *Hum Biol*, 1988, 60: 395–405
- 34 Wu X J, Liu W, Zhang Q, et al. The microevolution of the craniofacial morphological features for the Holocene human populations in north China. *Chinese Sci Bull*, 2007, 52: 1661–1668
- 35 MacLarnon A, Hewitt G P. The Evolution of human speech: The Role of enhanced breathing control. *Am J Phy Anthropol*, 1999, 109: 341–363

**Open Access** This article is distributed under the terms of the Creative Commons Attribution License which permits any use, distribution, and reproduction in any medium, provided the original author(s) and source are credited.